

Double-plate fixation together with bridging bone grafting in nonunion of femoral supracondylar, subtrochanteric, and shaft fractures is an effective technique

Mohsen Mardani-Kivi, Mahmoud Karimi Mobarakeh, Sohrab Keyhani & Zoleikha Azari

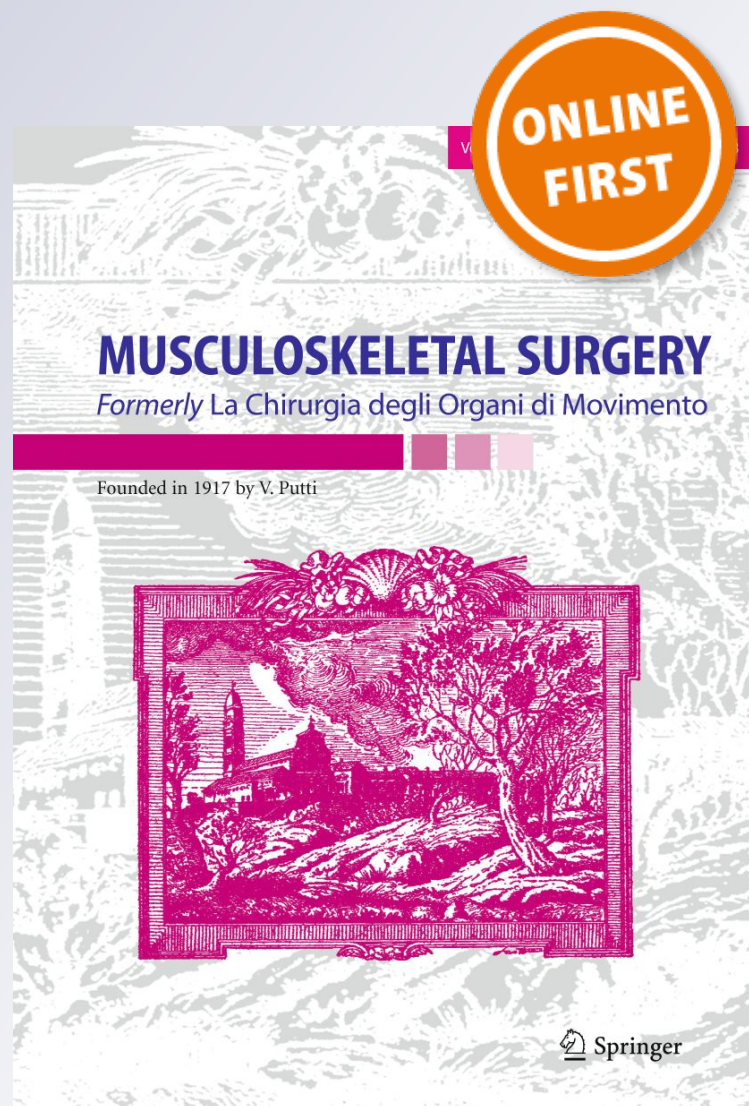
MUSCULOSKELETAL SURGERY

Formerly La Chirurgia degli Organi di Movimento

ISSN 2035-5106

Musculoskelet Surg

DOI 10.1007/s12306-019-00615-0



Your article is protected by copyright and all rights are held exclusively by Istituto Ortopedico Rizzoli. This e-offprint is for personal use only and shall not be self-archived in electronic repositories. If you wish to self-archive your article, please use the accepted manuscript version for posting on your own website. You may further deposit the accepted manuscript version in any repository, provided it is only made publicly available 12 months after official publication or later and provided acknowledgement is given to the original source of publication and a link is inserted to the published article on Springer's website. The link must be accompanied by the following text: "The final publication is available at link.springer.com".



Double-plate fixation together with bridging bone grafting in nonunion of femoral supracondylar, subtrochanteric, and shaft fractures is an effective technique

Mohsen Mardani-Kivi¹ · Mahmoud Karimi Mobarakeh² · Sohrab Keyhani³ · Zoleikha Azari^{4,5}

Received: 7 April 2018 / Accepted: 20 June 2019
© Istituto Ortopedico Rizzoli 2019

Abstract

Purpose The aims of the present study were to evaluate and report the therapeutic outcomes of double-plate fixation in combination with autogenous bridging bone grafting in treatment of nonunion fractures of femur.

Methods In this retrospective case series study, 41 patients with nonunion fracture of femur who underwent surgery by double-plate fixation and autogenous bridging bone grafting in academic referral center from July 2010 to July 2015 were enrolled. Totally, 32 males and 9 females with mean age of 35 years were evaluated. They were evaluated for related risk factors, previous therapeutic methods, time interval between injury to nonunion surgery and surgery to full clinical and radiological union, duration of follow-up, levels of postoperative limb shortening, and movement limitations.

Results Ten patients had open fractures and eight patients had infected nonunion in the femoral supracondylar, subtrochanteric, and shaft fractures. Nailing was the most common used method as the primary treatment of femoral shaft fractures. In addition, the mean follow-up time was 37 months. Full union was obtained even in infected cases. Deep vein thrombosis was found in one patient and pulmonary thromboembolism in another patient, and both patients were treated successfully. Moreover, limitations of articular movements were seen in seven patients.

Conclusion Double-plate fixation in combination with bridging bone grafting is an effective method in the treatment of nonunion of femoral supracondylar, subtrochanteric, and shaft fractures even in the infected cases.

Keywords Double plate · Bone graft · Nonunion · Femoral fracture

Introduction

According to the definition provided by the Food and Drug Administration (FDA), nonunion is the failure of complete healing of a bone fracture during the 9 months after injury. This time can differ based on the type of fractured bone, type and place of the fracture, and the conditions of the soft tissue. Nonunion is accompanied by persistent pain and/or motion of the fracture parts during weight-bearing conditions [1, 2].

Radiographic criteria of nonunion include lack of bone trabecular in the place of fracture, sclerotic edges, and stable lines of fracture. Furthermore, no evidence of progress toward recovery in serial radiography was seen for 3 consecutive months. The presence or absence of callus is not an index of nonunion because it is dependent on the site of the fracture and the type of healing [2]. Higher age, smoking, open fracture, level of bone fragmentation and soft tissue injuries, diabetes, severe anemia, malnutrition,

✉ Zoleikha Azari
fereshteh.azari90@gmail.com

¹ Ghaem Clinical Research Development Unit, Guilan University of Medical Sciences, Rasht, Iran

² Orthopedic Department, Kerman University of Medical Sciences, Kerman, Iran

³ Orthopedic Department, Akhtar Hospital, Shahid-Beheshti University of Medical Sciences, Tehran, Iran

⁴ Orthopedic Research Center, Guilan University of Medical Sciences, Rasht, Iran

⁵ Orthopedic Department, Poursina Hospital, Guilan University of Medical Sciences, Parastar Ave., Rasht 4137816375, Iran

low level of vitamin D₃, hypothyroidism, infections, consumption of nonsteroidal anti-inflammatory drugs (NSAIDs), and prednisolone are the risk factors for nonunion [3, 4]. Incidence of nonunion in fractures of long bones is 5–10%, but its incidence in femoral fractures is varied based on the type and area of fracture and also therapeutic techniques [3].

There are several methods for treatment of delayed union and nonunion of femoral bone such as dynamization, reamed nailing after plate, exchange reamed nailing, augmentative plate fixation, plate fixation, and bridging bone grafting [2]. Although exchange reamed nailing in cases with failure in treatment of nonunion by plate fixation method and use of augmentative plate fixation in treatment of intramedullary nailing that caused nonunion were reported by some studies [2, 5–8], no confirmed gold-standard method for treatment of nonunion in femoral bone fractures is presented. Therefore, the aims of the present study were to evaluate and report the therapeutic outcomes of double-plate fixation in combination with bridging bone grafting in treatment of nonunions of femoral fractures.

Methods

Patients

In this retrospective case series study, 41 patients with nonunion of femoral fractures who underwent double-plate fixation in combination with autogenous bridging bone grafting from July 2010 to July 2015 in academic referral center were evaluated. Nonunion was diagnosed in all patients by one surgeon (first author) based on clinical and radiological findings.

Surgical technique

Surgery was done by lateral approach to femur in the seven steps as follows (Fig. 1):

- **First step:** All previous lesions were removed during surgery, and fibrotic areas and bone sequestrs were debrided aggressively and completely. In addition, biopsy, antibiogram, and culture were done for all cases.
- **Second step:** Freshening of the end of the fracture was performed.

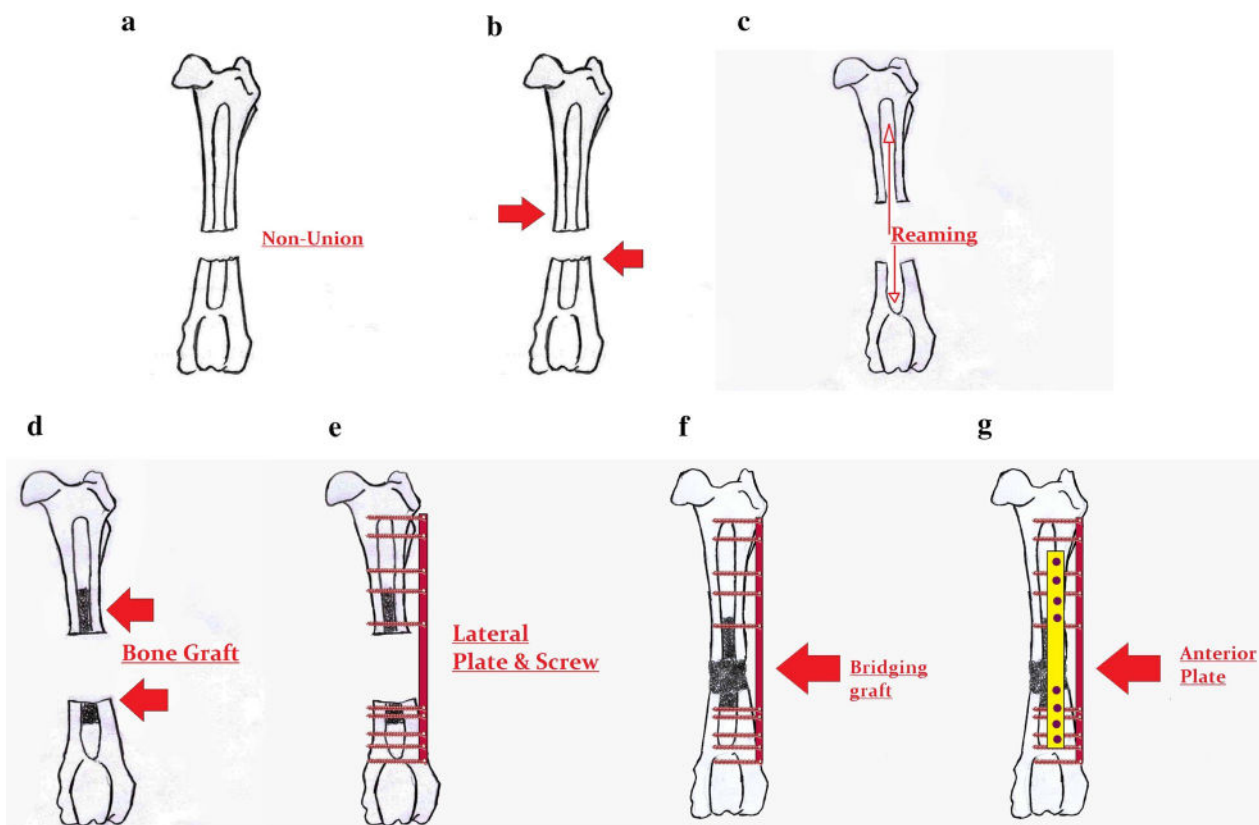


Fig. 1 Surgical technique; **a** first step, **b** second step, **c** third step, **d** fourth step, **e** fifth step, **f** sixth step, and **g** seventh step

- **Third step:** Opening of the medullary canal through fracture site was done.
- **Fourth step:** Obtained corticocancellous bone graft from iliac crest was placed in the medullary canal on both sides of nonunion site.
- **Fifth step:** By one lateral plaque, 10 cortices in each side of the fracture were picked up using five proximal and five distal screws.
- **Sixth step:** After placing the lateral plaque, the remained defect in the fracture area was filled by corticocancellous bone graft. Thus, grafts which were placed on both sides of the nonunion in the medullary canal were attached together as a bridge.
- **Seventh step:** Anterior plaque was placed by picking up eight cortices in each side of the fracture using 4 proximal and 4 distal screws.

It must be noted that in the nonunion of femoral supracondylar fractures, medial plaque was used instead of anterior plaque due to small size of the distal part of fracture. Prophylactic antibiotic therapy by intravenous administration of third generation of cephalosporin was started during the surgery and continued until 5 days after operation. Moreover, in the infected cases, patients received appropriated antibiotics parenterally for 2 weeks and then orally for 4 weeks. During hospitalization period, all patients received low molecular weight heparin.

Rehabilitation and evaluations

Rehabilitation exercises were begun from the first postoperative day. Toe-touch weight bearing by help of rod was continued for 6 weeks after operation. Then, weight bearing was done gradually based on the clinical and radiological improvements. Clinical union was defined as lack of pain in the full weight-bearing time. Radiological union was determined based on crossing of bone trabecular from at least 3 of 4 cortices in full and side view graphs of nonunion place. Outcomes were evaluated based on union, range of movement in neighboring joints, limb shortening, and medical or surgical complications. Also, clinical and radiological outcomes were evaluated by all authors.

Results

Totally, 32 males and 9 females with mean age of 35 years (range 18–71 years) were evaluated in this study. Among them, 32 patients (28 male and 4 female) had femoral shaft fracture, 5 patients (4 male and 1 female) had femoral subtrochanteric fracture, and 4 female patients had

femoral supracondylar fracture. Open fracture was seen in 5 of 32 femoral shaft fractures, 1 of 5 femoral subtrochanteric fractures, and all of femoral supracondylar fractures.

Eight patients had infected nonunions which included three patients with femoral shaft fractures, two patients with femoral subtrochanteric fracture and three patients with femoral supracondylar fracture. Among them, *Staphylococcus aureus* was detected in culture of surgical specimen of 3 patients who were treated with appropriated antibiotic based on antibiogram.

Smoking was the most prevalent risk factor and 56% of patients consumed more than 1 pack-year of cigarettes.

One packet in a year. Nailing was the most common therapeutic method in primary treatment of femoral shaft fracture (78%). Mean time interval between primary injuries to nonunion treatment was about 19 months (range 9–36 months). Mean time interval between surgery and full clinical and radiological union was about 5 months (range 4–8 months). Full union was obtained in all patients even in infected cases. The mean follow-up time was 37 months (range 18–63 months). Three patients suffered limb shortening more than 10 mm after surgery. Among them two patients (one patient with nonunion of femoral shaft fracture and one patient with nonunion of femoral subtrochanteric fracture) had 15-mm limb shortening after surgery. Another patient who had nonunion of femoral supracondylar fracture suffered 20-mm limb shortening.

Also, lesions in the fracture site and iliac crest were healed in all patients. Postoperative severe complications were seen in two patients which included deep vein thrombosis (DVT) in one patient with nonunion of femoral subtrochanteric fracture and pulmonary thromboembolism in another patient with nonunion of femoral supracondylar fracture. Both complications were treated successfully by expert medical team.

At the final follow-up, across 32 patients with nonunion of femoral shaft fracture, three patients had 10°–20° movement limitations in knee flexion. Among five patients with nonunion of femoral subtrochanteric fracture, one patient had 10° movement limitations in hip flexion and extension. Finally, across four patients with nonunion of femoral supracondylar fracture, three patients had 20°–30° and 10° movement limitations in knee flexion and extension, respectively. Figures 2, 3, 4, 5, 6, 7, 8, 9, 10, 11, 12, 13, and 14 demonstrated the changes before and after surgery in 13 of our patients.

Risk factors, previous therapeutic methods, time interval between primary injuries to nonunion surgery and from surgery to full clinical and radiological union, duration of follow-up, and postoperative movement limitations in each patient are reported in Table 1.

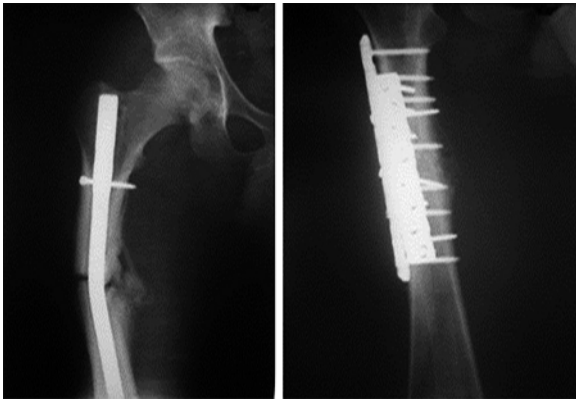


Fig. 2 Preoperative (left) and postoperative (right) chasis number 2 (Table 1)

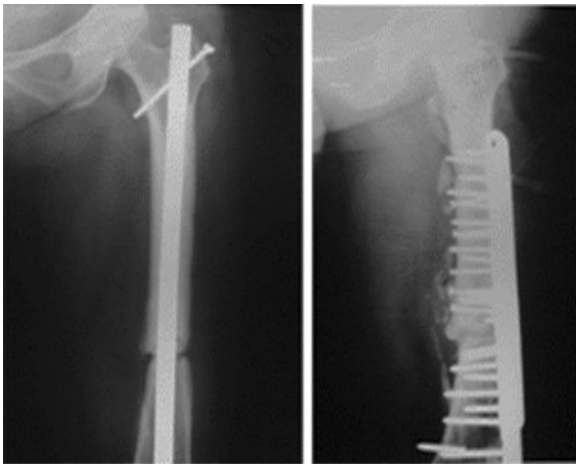


Fig. 3 Preoperative (left) and postoperative (right) chasis number 6 (Table 1)

Discussion

Nonunion is a delayed complication of bone fractures and one of the most important problems in the therapeutic trend of long bone fractures. Since the introduction of intramedullary nails method in treatment of long bone fracture by Küntscher in 1939, several studies have been performed to find the appropriate method for prevention of nonunion in treatment of fractures of such bones. However, rare studies were performed in cases with occurrence of nonunion, and no gold-standard method for these cases exists [9–11].

In the present study, double-plate fixation in combination with bridging bone grafting was used as a method in the treatment of nonunion of femoral fractures. In this method, aggressive debridement of fibrotic area and bone

sequesters, freshening of fractures end sides, opening of medullary canal, application of corticocancellous bone graft as impacted bridging in the medullary canal, and rigid fixation by two plaques induced significant therapeutic success during 5 months and considerably early weight bearing. As a notable point, all patients, even infected cases, showed full union after using this method.

In a similar study by Odeh and colleagues, the outcomes of rigid internal fixation in combination with autogenous bone grafting in treatment of nonunion of femoral shaft fractures during 11 years were evaluated. In their study, free non-vascularized half fibula graft which was obtained from the mid part of this bone was replaced in the medullary canal. Then, double-plate fixation using two plaques in lateral and anterior of fracture site was done and finally autogenous anterior iliac crest bone graft was applied in all patients. Using this method caused full clinical and radiological union in their 21 evaluated patients [12]. Albeit we just used corticocancellous bone graft obtained from iliac crest as impacted in the medullary canal on both sides of the nonunion, Odeh and colleagues used intramedullary half fibula graft in addition to iliac crest. Furthermore, in another similar study by Maimaitiyiming and coworkers, clinical outcomes of double-plate fixation in combination with autogenous bone grafting in the treatment of nonunion of femoral shaft fractures during 3 years were evaluated. In their method, a long anterolateral incision (15 cm) was created in the mid third of the middle part of femoral shaft on the nonunion area. Then a locking compression plate (10–11 holes, 4.5/5.0 mm broad) was placed on the lateroproximal part of femur and fixed using appropriate number of locked and unlocked screws. Autologous bone grafts which were obtained from iliac crest were divided into small pieces and placed in the bone defect. Finally, another locking plate (8–9 holes, 4.5/5.0 mm broad) with suitable size and angle against first plate was placed similarly on the anterior of femur and fixed with at least four screws. All 14 patients achieved full union. Although in these two studies only patients with aseptic nonunion of femoral shaft fractures were evaluated, successful outcomes of this method, similar to our study, confirms the effectiveness of rigid fixation together with bone grafting in the treatment of nonunion of femoral shaft fractures. In addition, this strategy due to the strong fixation by three-dimensional fixation and application of bone grafting can be considered as an effective method in the treatment of nonunion with bone defect related to failure of treatment by repeated plate or intramedullary nail fixation [13].

Use of medial plaque through lateral approach in nonunion of femoral supracondylar fracture is a difficult subjective technique due to the small size of distal part of fracture. But this technique in all cases of our study showed successful outcomes, and specifically, it must be noted that 3 of 4 cases of nonunion of femoral supracondylar fracture in our study

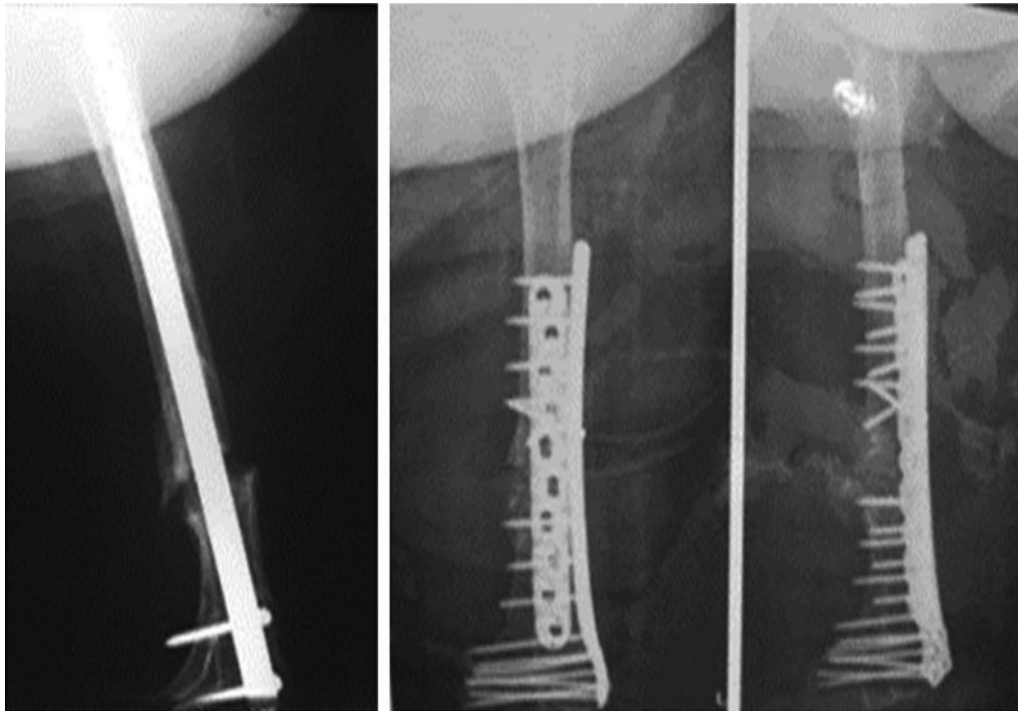


Fig. 4 Preoperative (left) and postoperative (right) chassis number 7 (Table 1)

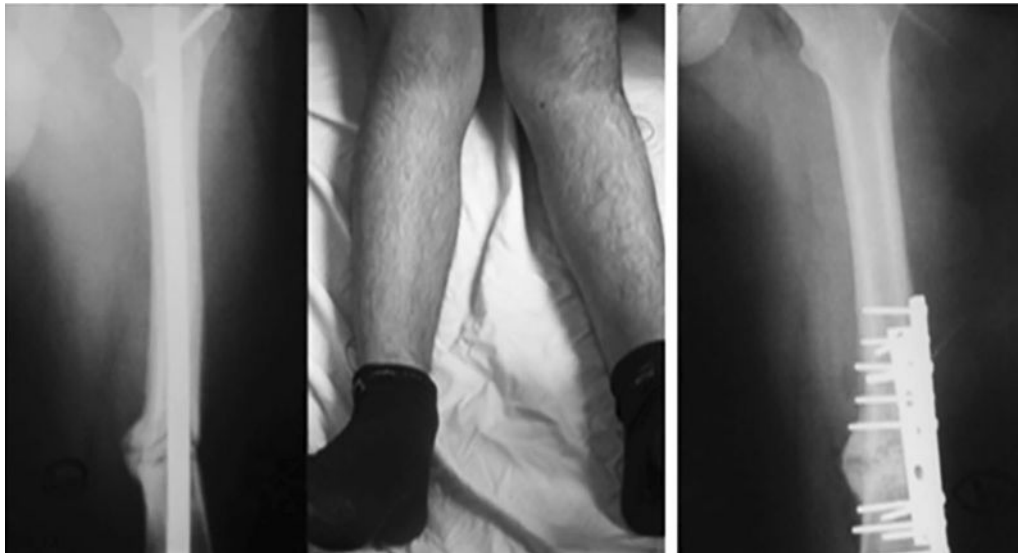


Fig. 5 Preoperative (left) and postoperative (right) chassis number 15 (Table 1)

were infected. In the study by Chapman and collaborators, the outcomes of single- and double-plate fixation in combination with bone grafting from iliac crest in treatment of nonunion of femoral supracondylar fractures were evaluated. In their study, 13 double-plate, 4 single-plate, and 1 interfragmentary screws were used for fixation of nonunion and autologous bone graft. Their results showed that rigid plate

fixation and autologous bone grafting were effective in the treatment of nonunion of femoral supracondylar fractures [14]. In our study, a higher number of patients (32 male and 9 female) with broader age range (mean age of 35 years and age range of 18–71 years) were evaluated in comparison with previous studies. For instance, 21 patients including 17 males and 4 females with mean age of 32 years and age

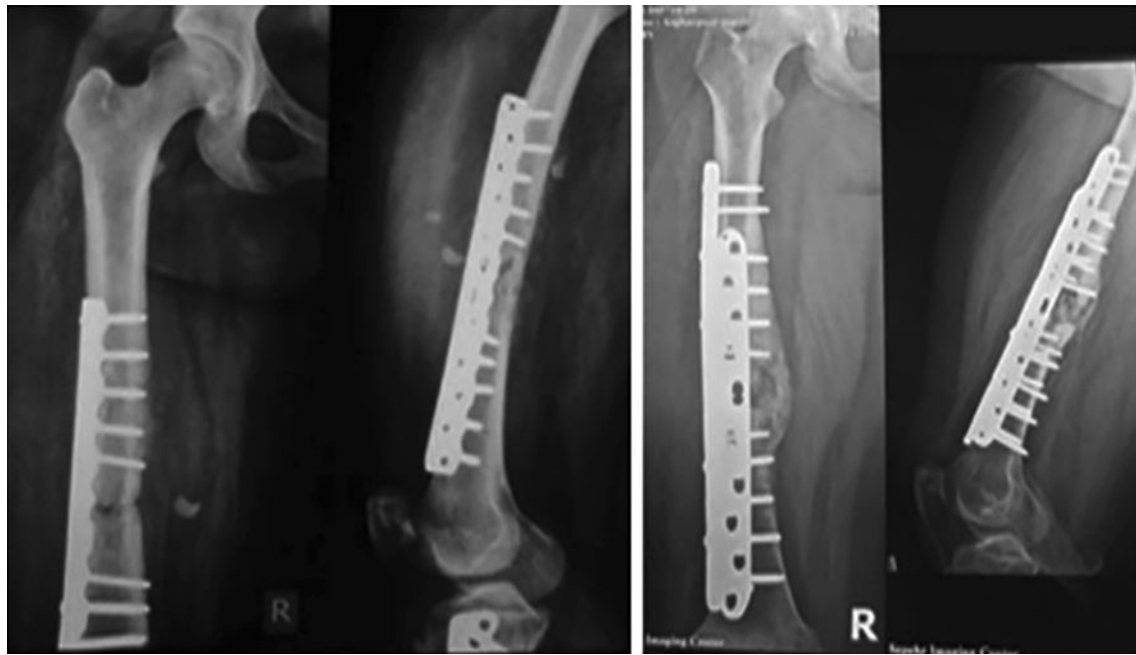

Fig. 6 Preoperative (left) and postoperative (right) chassis number 19 (Table 1)

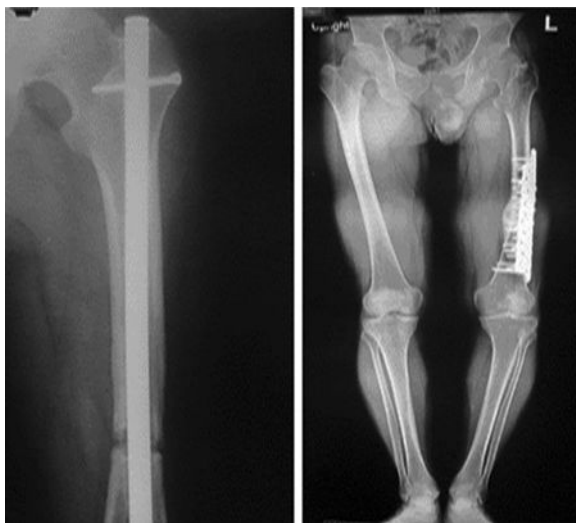

Fig. 7 Preoperative (left) and postoperative (right) chassis number 22 (Table 1)

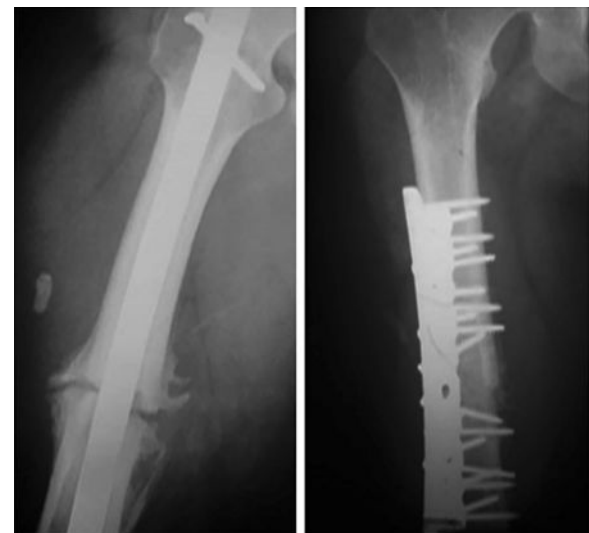

Fig. 8 Preoperative (left) and postoperative (right) chassis number 27 (Table 1)

range of 16–52 years in the study of Odeh et al. [12], 14 patients including 9 males and 5 females with mean age of 26 years and age range of 22–32 years in the study of Maimaitiyiming et al. [13], and 18 adult patients in the study of Chapman et al. [14].

In the present study, outcomes of application of double-plate fixation in combination with bridging bone grafting in three groups of patients with nonunion of femoral subtrochanteric, supracondylar, and shaft fractures were evaluated, simultaneously. In the study of Odeh and colleagues and

Maimaitiyiming et al., all evaluated patients had femoral shaft fracture. Also, in the study of Chapman and coworkers, all patients had femoral supracondylar fracture [12–14].

In the present study, eight patients had infected nonunion of femoral fracture, and all of them were treated successfully, whereas the double-plate fixation in combination with bone grafting was not evaluated on similar patients in any of the previous studies. In line with our study, Odeh et al. [12] reported that nailing was the most common used

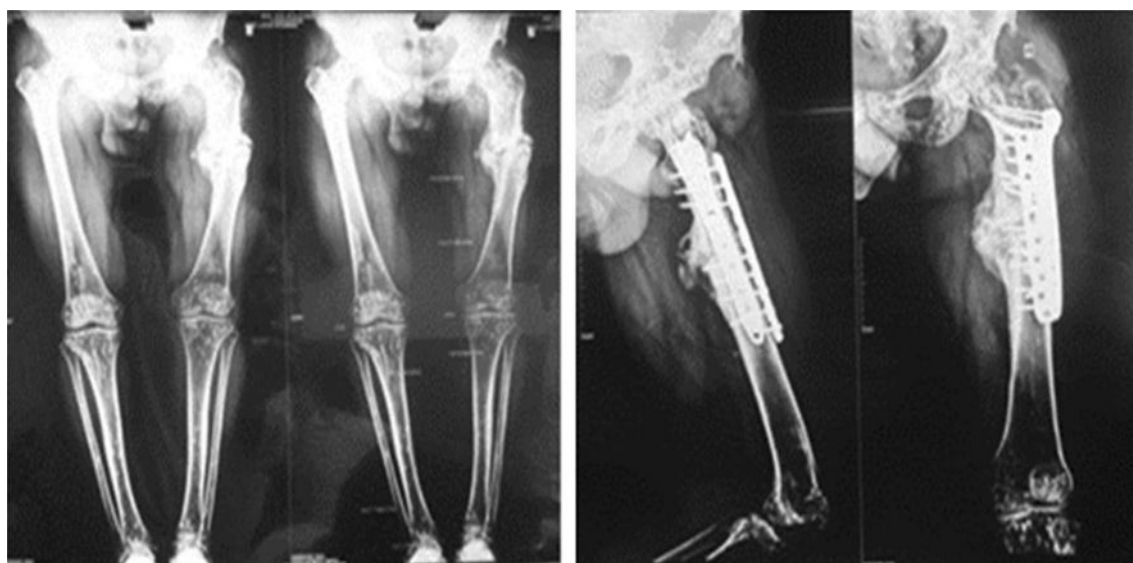


Fig. 9 Preoperative (left) and postoperative (right) chassis number 30 (Table 1)

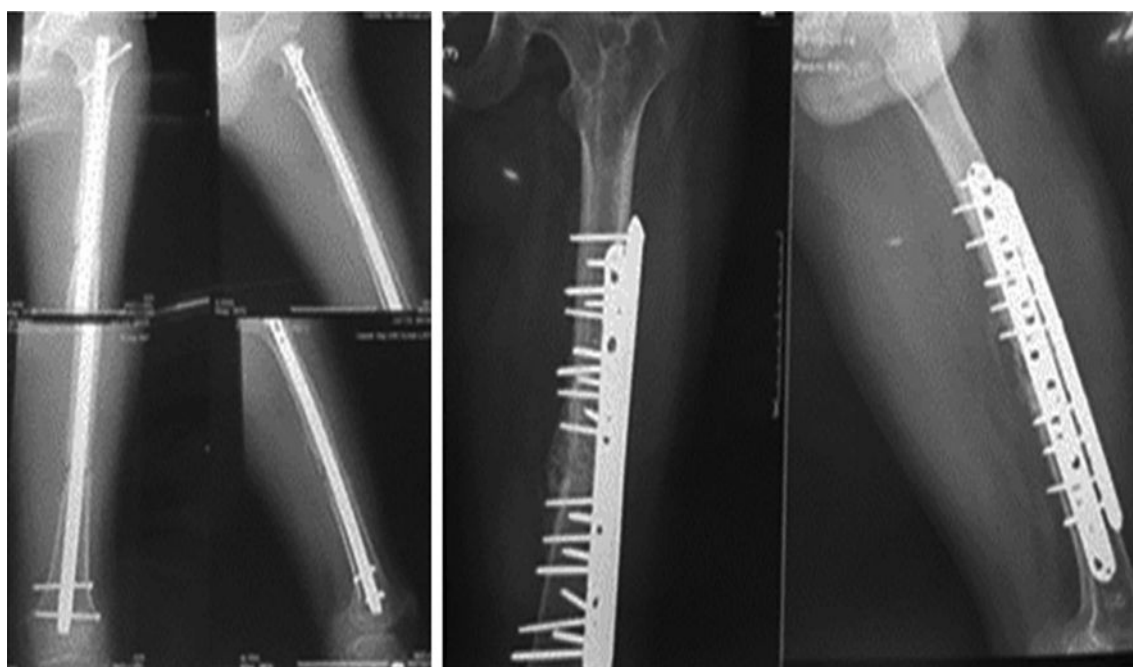


Fig. 10 Preoperative (left) and postoperative (right) chassis number 32 (Table 1)

method in the primary treatment of femoral shaft fracture. Furthermore, smoking was the most prevalent risk factor of nonunion in our study, similar to that reported by Odeh et al. [12] and Chapman et al. [14]. Additionally, 10 of our patients had open fracture which is an important risk factor for nonunion of femoral fractures.

Mean time interval between primary injuries to nonunion treatment was 19 months (range 9–36 months) which

was higher than those reported by Odeh et al. (mean of 13 months, range 6–23 months) and Chapman et al. (mean of 15 months, range 5–36 months) but lower than mean of 26.2 months that was reported by Maimaitiyiming and coworkers [12–14]. As a notable finding, the mean time interval between surgery and full clinical and radiological union was 5 months (range 4–8 months) which was lower than all of the previous reports. For instance, this time was reported as

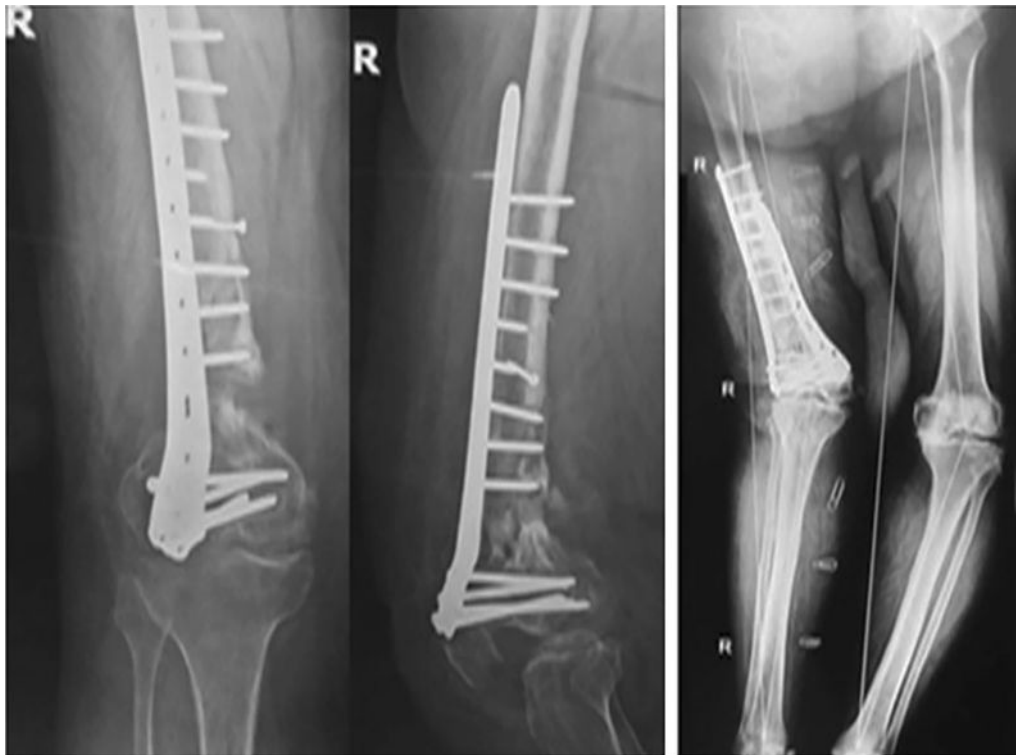

Fig. 11 Preoperative (left) and postoperative (right) chassis number 35 (Table 1)

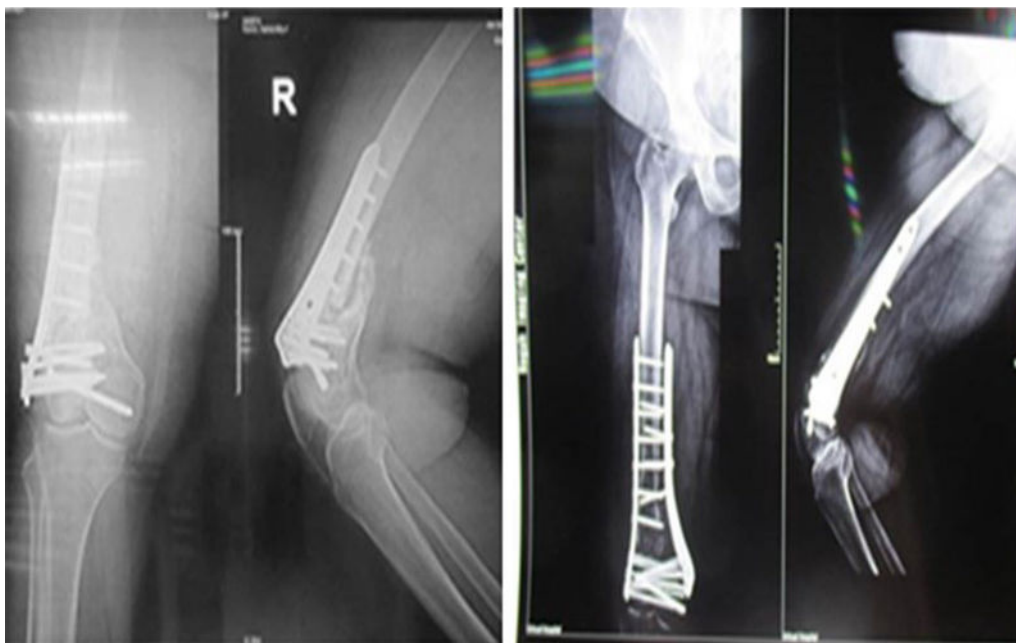

Fig. 12 Preoperative (left) and postoperative (right) chassis number 36 (Table 1)

11 months (range 9–14 months) by Odeh and colleagues, 15 months (range 5–36 months) by Chapman and collaborators, and 5.2 months (range 4–7 months) by Maimaitiyiming

and coworkers [12–14]. Moreover, mean follow-up time in our study was 36 months (range 18–63 months) which was higher than all previous studies reported by Odeh

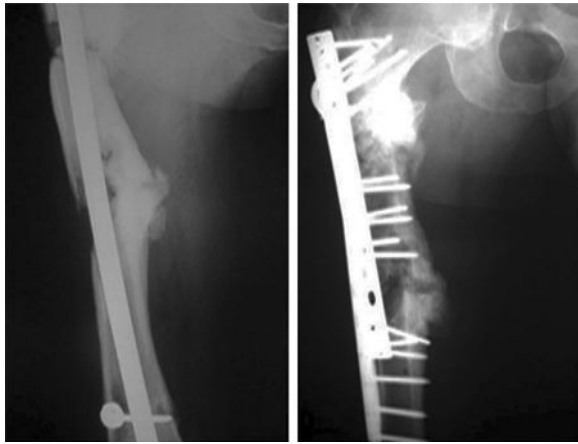


Fig. 13 Preoperative (left) and postoperative (right) chassis number 39 (Table 1)

et al. (30 months, range 24–40 months), Chapman et al. (26 months, range 6–120 months), and Maimaitiyiming et al. (14.8 months, range 10–25 months) [12–14].

In the study of Odeh and coworkers, mean of limb shortening was 5 mm, and seven patients had 10-mm limb shortening after surgery [12]. In the present study, just three patients had postoperative limb shortening more than 10 mm and among them two patients had infected nonunion. Cases with limb shortening lower than 10 mm were not considerable.

In our study, DVT and pulmonary thromboembolism, as two postoperative acute complications, were seen in two patients. In the study of Odeh et al., postoperative acute complications were seen in four patients and included

suspected pneumonia (2 cases) and DVT without pulmonary thromboembolism (two cases), and all of them were treated successfully [12]. In the study of Chapman and coworkers, postoperative complications were seen in two patients and included infection with loss of knee movement which was treated by debridement and antibiotic therapy. Another complication was malunion [14].

In the final follow-up, seven patients had limitation in joint movement. This situation was seen in three patients in the study of Odeh et al. as decrease in hip abduction to 10°, decrease in hip external rotation to 10°, decrease of hip flexion to 80°, and decrease of knee flexion to 90° in one patient, decrease of knee flexion to 110° and 100° in another two patients, respectively [12]. Furthermore, mean of knee movement range at the final follow-up was 101° (range 10°–135°) which was reported by Chapman and colleagues [14].

Conclusion

Double-plate fixation in combination with bridging bone grafting is an effective method in the treatment of nonunion of femoral subtrochanteric, supracondylar, and shaft fractures even in infected cases.

Compliance with ethical standards

Conflict of interest Authors declare that they have no conflict of interest.

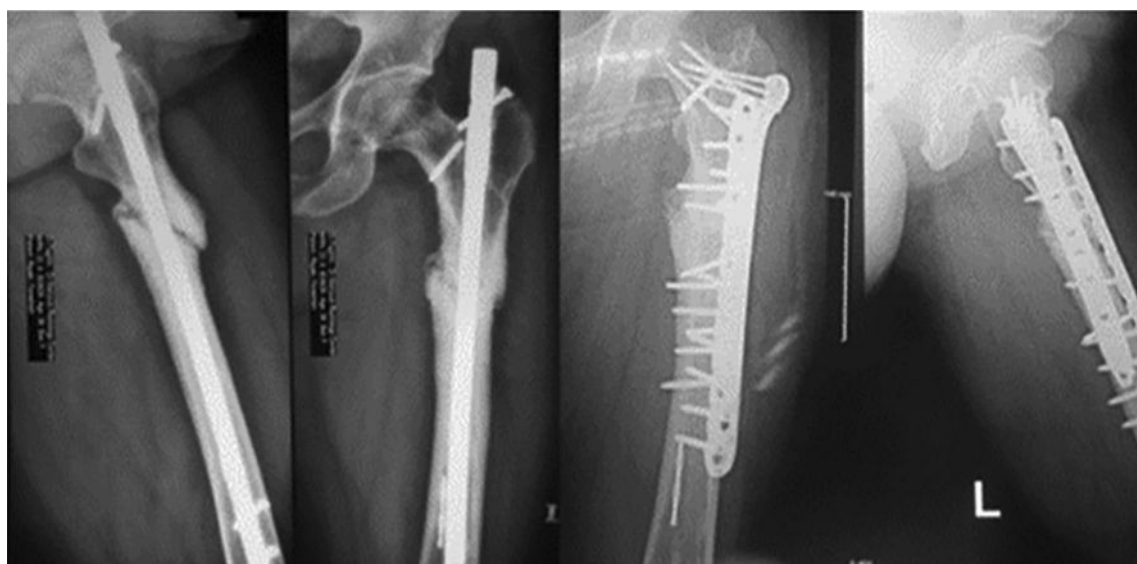

Fig. 14 Preoperative (left) and postoperative (right) chassis number 40 (Table 1)

Table 1 Preoperative and postoperative data analysis for 41 patients

No.	Sex (M/F)	Age (years)	Type of nonunion fracture	Previous treatment	Risk factors	Interval from injury to operation (months)	Time to full clinical and radiological union (months)	Length of follow-up (months)	limitation of movements	Nonunion type
1	M	39	Femoral shaft (infected)	Nailing	OF, S	9	7	63	Knee flexion (10°)	Atrophic
2	M	25	Femoral shaft	Nailing	S, NS	15	5	42	—	Hypertrophic
3	M	42	Femoral shaft	Plating	S	18	4	38	—	Hypertrophic
4	F	31	Femoral shaft	Nailing	DM	19	4	36	—	Eutrophic
5	M	36	Femoral shaft	Nailing dynamization	S	20	4	32	—	Hypertrophic
6	M	18	Femoral shaft	Nailing	S	22	5	37	—	Eutrophic
7	F	70	Femoral shaft	Nailing	OF	20	5	40	—	Eutrophic
8	M	29	Femoral shaft	Nailing	NS	17	5	41	—	Hypertrophic
9	M	26	Femoral shaft	Traction external	DM	18	5	42	—	Hypertrophic
10	M	31	Femoral shaft	Nailing	OF	25	7	18	—	Hypertrophic
11	M	35	Femoral shaft	Grafting	S	19	4	34	—	Hypertrophic
12	M	34	Femoral shaft	Nailing	NS	14	4	39	—	Eutrophic
13	M	39	Femoral shaft	Nailing	S	21	4	30	—	Eutrophic
14	M	19	Femoral shaft	Traction external	S	18	4	35	—	Hypertrophic
15	M	18	Femoral shaft	Nailing	NS	14	5	33	Knee flexion (10°)	Atrophic
16	M	22	Femoral shaft	Nailing	NS	16	5	22	—	Eutrophic
17	M	60	Femoral shaft	Plating	OF	23	5	36	—	Hypertrophic
18	M	26	Femoral shaft	Nailing	S	16	5	34	—	Eutrophic
19	M	38	Femoral shaft (infected)	Nailing	S, NS	22	8	32	—	Atrophic
20	M	29	Femoral shaft	Nailing dynamization	S	20	4	30	—	Eutrophic
21	M	25	Femoral shaft	Nailing exchange	S	16	4	42	—	Eutrophic
22	F	71	Femoral shaft	Nailing	DM	10	4	41	—	Atrophic
23	M	27	Femoral shaft	Plating	NS	18	5	59	—	Eutrophic
24	M	23	Femoral shaft	Nailing	S	15	4	38	—	Eutrophic
25	M	20	Femoral shaft	Grafting	S	25	4	60	—	Hypertrophic
26	M	42	Femoral shaft	Nailing dynamization	S	9	6	36	—	Hypertrophic
27	M	44	Femoral shaft	Nailing	NS	16	5	37	Knee flexion (20°)	Atrophic
28	M	54	Femoral shaft	Nailing exchange	DM	18	4	27	—	Hypertrophic
29	M	25	Femoral shaft	Nailing	S	20	6	20	—	Hypertrophic

Table 1 (continued)

No.	Sex (M/F)	Age (years)	Type of nonunion fracture	Previous treatment	Risk factors	Interval from injury to operation (months)	Time to full clinical and radiological union (months)	Length of follow-up (months)	limitation of movements	Nonunion type
30	M	31	Femoral shaft (infected)	Nailing dynamization	OF, S	11	7	55	–	Atrophic
31	M	36	Femoral shaft	Nailing	S	19	6	39	–	Eutrophic
32	F	29	Femoral shaft	Nailing	S	18	5	31	–	Eutrophic
33	F	23	Supracondylar (infected)	Plating	OF, S	22	6	34	Knee flexion (20°)	Atrophic
34	F	40	Supracondylar	Plating	NS	22	4	19	–	Atrophic
35	F	65	Supracondylar (infected)	Plating	S	36	7	30	Knee flexion (30°)	Atrophic
36	F	32	Supracondylar (infected)	Plating	DM	18	6	58	Knee extension (10°)	Atrophic
37	M	65	Subtrochanteric	Nailing	S	20	4	33	–	Atrophic
38	F	41	Subtrochanteric	Nailing	OF, NS	26	4	30	Hip flexion and extension (10°)	Atrophic
39	M	35	Subtrochanteric (infected)	Nailing	OF	15	8	35	–	Atrophic
40	M	42	Subtrochanteric (infected)	Nailing	OF, S	20	7	20	–	Atrophic
41	M	18	Subtrochanteric	Nailing	OF	10	4	63	–	Atrophic

OF open fracture, S smoking, NS NSAIDs, DM diabetes mellitus

Ethical approval This article does not contain any studies with animals performed by any of the authors. This article does not contain any studies with human participants performed by any of the authors.

References

1. Brinker MR (2003) Skeletal trauma: basic science management, and reconstruction, 3rd edn. Saunders, Philadelphia
2. van den Somford MPJ, Bekerom MPJ, Kloen P (2013) Operative treatment for femoral shaft nonunions, a systematic review of the literature. *Strateg Trauma Limb Reconstr* 8:77–88
3. Zura R, Mehta S, Della Rocca GJ, Steen RG (2016) Biological risk factors for nonunion of bone fracture. *JBJS Rev* 4(1):e2
4. Giannoudis PV, MacDonald DA, Matthews SJ et al (2000) Nonunion of the femoral diaphysis. *J Bone Joint Surg Br* 82:655–658
5. Vaughn J, Gotha H, Cohen E, Fantry AJ, Feller RJ, Meter V et al (2016) Nail dynamization for delayed union and nonunion in femur and tibia fractures. *Orthopedics* 39(6):e1117–e1123
6. Wu CC (2003) Reaming bone grafting to treat tibial shaft aseptic nonunion after plating. *J Orthop Surg (Hong Kong)* 11(1):16–21
7. Weresh MJ, Hakanson R, Stover MD et al (2000) Failure of exchange reamed intramedullary nails for ununited femoral shaft fractures. *J Orthop Trauma* 14–5:335–338
8. Hierholzer C, Glowalla C, Herrler M, Rüdén C, Hungerer S, Bühren V et al (2014) Reamed intramedullary exchange nailing: treatment of choice of aseptic femoral shaft nonunion. *J Orthop Surg Res* 9(1):1
9. Böhler L (1943) Vorschlag zur Marknagelung nach Ku`ntscher bei frischen Oberschenkelschussbru`chen. *Der Chirurg* 15–1:8–13
10. Ebraheim NA, Martin A, Sochacki KR, Liu J (2013) Nonunion of distal femoral fractures: a systematic review. *Orthop Surg* 5:46–50
11. Attal R, Blauth M (2010) Unreamed intramedullary nailing. *Orthopade* 39–2:182–191
12. Odeh R, Al-Karmi S, Odeh M, Bakir W (2015) Double plating with autogenous bone grafting in the treatment of non-union of femoral shaft fractures. *J R Med Serv* 22(1):6–12
13. Maimaitiyiming A, Amat A, Rehei A, Tusongjiang M, Li C (2015) Treatment of the femoral shaft nonunion with double plate fixation and bone grafting: a case series of 14 patients. *Injury* 46(6):1102–1107
14. Chapman MW, Finkemeier CG (1999) Treatment of supracondylar nonunions of the femur with plate fixation and bone graft. *J Bone Joint Surg Am* 81(9):1217–1228

Publisher's Note Springer Nature remains neutral with regard to jurisdictional claims in published maps and institutional affiliations.